



Ranid and Bufonid Herpesvirus Skin Disease

Agent

The herpesviruses are a diverse group of viruses, two of which are known to affect wild amphibians in Europe. Infection with ranid herpesvirus 3 (RHV3) is known to cause skin lesions in frogs in the family Ranidae. Bufonid herpesvirus (BfHV1) has been identified as the cause of skin lesions in common toads (*Bufo bufo*).

Species affected

In Great Britain, ranid herpesvirus skin disease has only been reported in the common frog (*Rana temporaria*). Whilst bufonid herpesvirus skin disease has not been detected in Great Britain, it is known to affect common toads in Switzerland.

Clinical signs

Frogs with ranid herpesvirus skin disease develop skin abnormalities which look like grey or white-coloured warty lesions. These lesions are often described as 'candle wax-like lesions' as they look as if candle wax has been dripped onto the affected frog's skin. The disease appears in early spring, usually during the breeding season when frogs are spawning, and then regresses over the late spring and summer. Little is known about this disease but affected frogs do not appear to suffer any ill effects from having temporarily warty skin.

Common toads infected with BfHV1 also tend to develop skin abnormalities during the breeding season, which look like raised black or dark brown patches that can join together to form large lesions. However, unlike ranid herpesvirus skin disease, there is some evidence that common toads with bufonid herpesvirus skin disease may become ill with associated mortality. Further investigation is required to determine the clinical significance of this disease on common toad health.



Figure 1. Common frog (*Rana temporaria*) with ranid herpesvirus skin disease
Photo credit: Sarah Reed

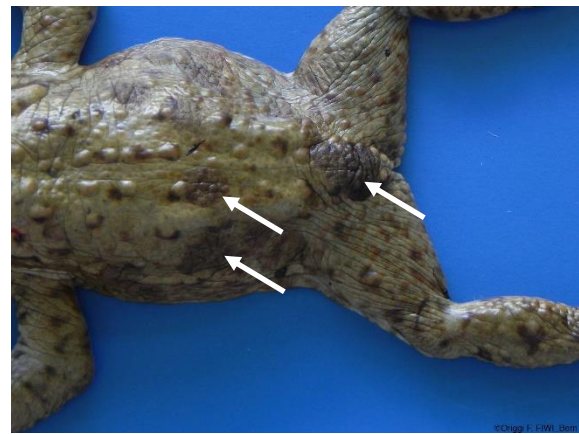


Figure 2. Common toad (*Bufo bufo*) with bufonid herpesvirus 1 associated skin disease (white arrows)
Photo credit: Francesco C. Origi

Disease transmission

It is not known how either of these viruses are transmitted between amphibians.

Distribution

In Great Britain, ranid herpesvirus skin disease has been reported from multiple sites across England and Wales since the early 1990s.

At this time, bufonid herpesvirus skin disease has only been reported in Switzerland, where it has been detected at several sites since 2014. As yet, BfHV1 has not been detected in Great Britain and it is not yet known if this virus is present in this country.

Risk to human health

Ranid and bufonid herpesviruses are only known to infect amphibians and pose no known threat to human health.

Risk to domestic animal health

Ranid herpesviruses are only known to infect frogs in the family Ranidae. Pet ranid frogs might, therefore, be susceptible to ranid herpesvirus skin disease.

Although no other species of toad has been reported to be affected by bufonid herpesvirus skin disease, it is possible that they may also be susceptible to infection with BfHV1.

Diagnosis

Ranid and bufonid herpesvirus skin disease often produce characteristic skin lesions at a specific time of the year. It is possible that the causative viruses can result in less-obvious skin lesions or other abnormalities which have not yet been discovered. Confirmation of disease and investigations for ranid and bufonid herpesvirus infection require specialist laboratory tests.

If you wish to report finding a dead amphibian, or signs of disease in amphibians, please visit www.gardenwildlifehealth.org. Alternatively, if you have further queries or have no internet access, please call the **Garden Wildlife Health** vets on **0207 449 6685**.

Further information

More advice on amphibians in your garden can be found on the Garden Wildlife Health website www.gardenwildlifehealth.org.

Scientific publications

Franklinos LHV, Rodriguez-Ramos Fernandez, J, Hydeskov HB, Hopkins KP, Everest DJ, Cunningham AA, Lawson B (2018) Herpesvirus skin disease in free-living common frogs *Rana temporaria* in Great Britain. *Diseases of Aquatic Organisms* **129**:239–244. doi.org/10.3354/dao03246

Origgi FC, Schmidt BR, Lohmann P, Otten P, Meier RK, Pisano SRR, Moore-Jones G, Tecilla M, Sattler U, Wahli T, Gaschen V, Stoffel MH (2018) *Bufonid herpesvirus 1* (BfHV1) associated dermatitis and mortality in free ranging common toads (*Bufo bufo*) in Switzerland. *Scientific Reports* **8**:14737. [doi: 10.1038/s41598-018-32841-0](https://doi.org/10.1038/s41598-018-32841-0)

Origgi FC, Schmidt BR, Lohmann P, Otten P, Akdesir E, Gaschen V, Aguilar-Bultet L, Wahli T, Sattler U, Stoffel MH (2017) Ranid Herpesvirus 3 and Proliferative Dermatitis in Free-Ranging Wild Common Frogs (*Rana temporaria*). *Veterinary Pathology* **54**(4):686-694. doi.org/10.1177/0300985817705176

Van Beurden S and Engelsma M (2012) Herpesviruses of Fish, Amphibians and Invertebrates. *In Herpesviridae - a look into this unique family of viruses*. Magel, GDM Ed., Intech books, pp. 217-242 IntechOpen. [doi:10.5772/29575](https://doi.org/10.5772/29575).

Bennati R, Bonetti M, Lavazza A, Gelmetti D (1994) Skin lesions associated with herpesvirus-like particles in frogs (*Rana dalmatina*), *Veterinary Record* **135**(26):625-626. [doi:10.1136/vr.135.26.625](https://doi.org/10.1136/vr.135.26.625).

Acknowledgements

Funding for the GWH comes in part from Defra, the Welsh Government and the Animal and Plant Agency (APHA) Diseases of Wildlife Scheme (DoWS) <http://ahvla.defra.gov.uk/vet-gateway/surveillance/seg/wildlife.htm>; and from the [Esmée Fairbairn Foundation](#), the [Universities Federation for Animal Welfare](#) and [the Banister Charitable Trust](#).

Disclaimer

This fact sheet was produced by Garden Wildlife Health (GWH) for information purposes only. The GWH will not be liable for any loss, damage, cost or expense incurred in or arising by reason of any person relying on information in this fact sheet.

Date of factsheet update: April 2020